

3-2023

## **HUTCH DIVERTICULUM: A RARE CONGENITAL URINARY BLADDER DIVERTICULUM IN AN ELDERLY MALE PATIENT.**

Dr Rudresh Hiremath  
JSSAHER

Dr Shwetha Poojari  
JSSAHER, shwetapoojary113@gmail.com

Follow this and additional works at: <https://rescon.jssuni.edu.in/radiologyteachingfiles>



Part of the [Dentistry Commons](#), [Health Policy Commons](#), [Medical Education Commons](#), [Pharmacy and Pharmaceutical Sciences Commons](#), and the [Public Health Education and Promotion Commons](#)

---

### **Recommended Citation**

Hiremath, Dr Rudresh and Poojari, Dr Shwetha, "HUTCH DIVERTICULUM: A RARE CONGENITAL URINARY BLADDER DIVERTICULUM IN AN ELDERLY MALE PATIENT." (2023). *Radiology Teaching Files*. 21.  
<https://rescon.jssuni.edu.in/radiologyteachingfiles/21>

This Uroradiology Imaging is brought to you for free and open access by Research Connect. It has been accepted for inclusion in Radiology Teaching Files by an authorized administrator of Research Connect.

**CASE TITLE:** HUTCH DIVERTICULUM: A RARE CONGENITAL URINARY BLADDER DIVERTICULUM IN AN ELDERLY MALE PATIENT.

**CLINICAL HISTORY:** 54 year old male patient presented with burning micturition and increased frequency of urination for the last two months. He also gives history of intermittent episodes of high grade fever with chills and rigors.

**IMAGES:**

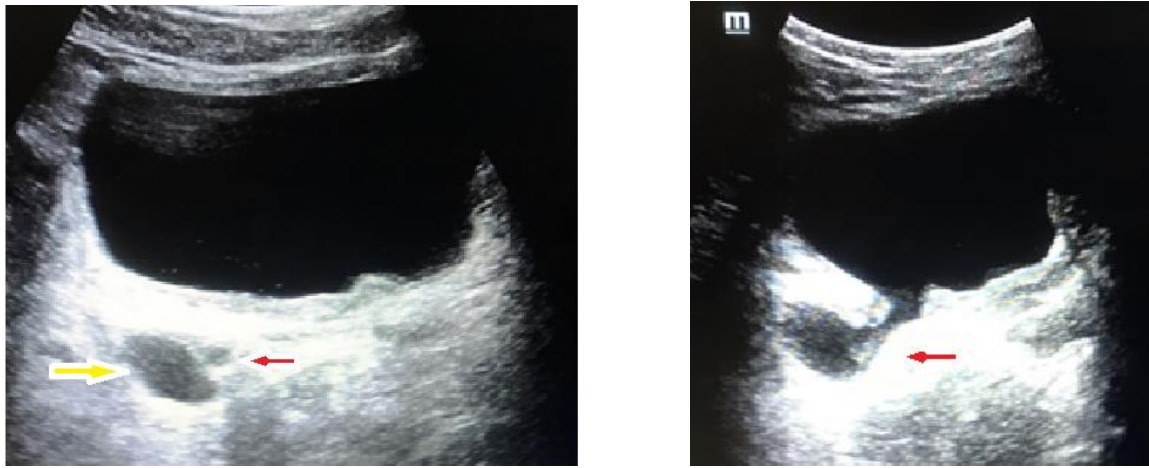


Figure 1. Ultrasound pelvis showing bladder diverticulum (yellow arrow) arising in the vicinity of right vesicoureteric junction (VUJ). Mild dilatation of right distal ureter (red arrow) is seen in its medial relation.

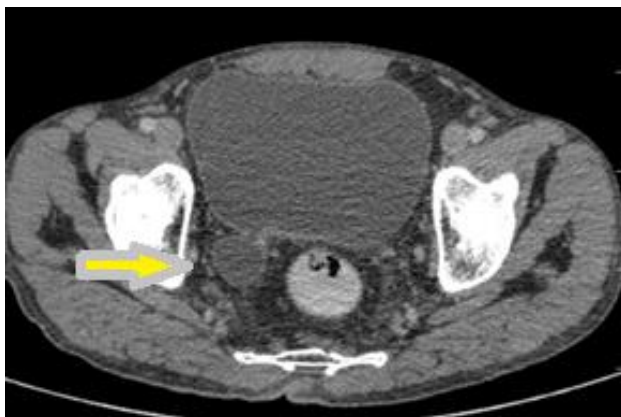


Figure 2. CECT pelvis Axial venous phase sections of urinary bladder depicting urine filled diverticulum (yellow arrow) arising from the right posterolateral wall.

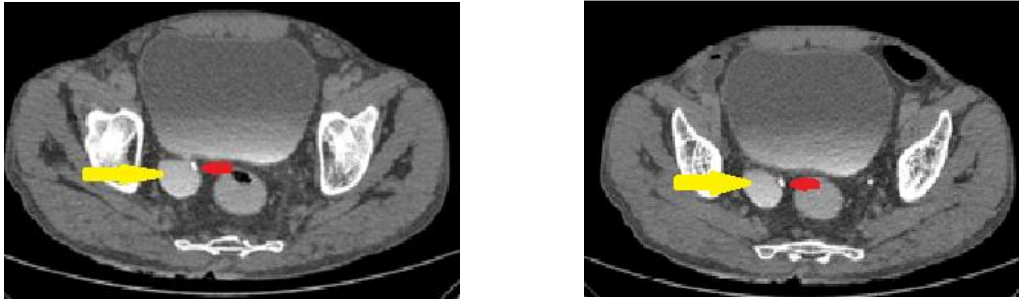


Figure 3. CT urography delayed axial images (a) and (b) showing a well-defined saccular outpouching (yellow arrow) arising from the right posterolateral wall of urinary bladder adjacent to the right vesico-ureteric junction. Contrast filled right ureter (red arrow) is traversing medial to the diverticulum.

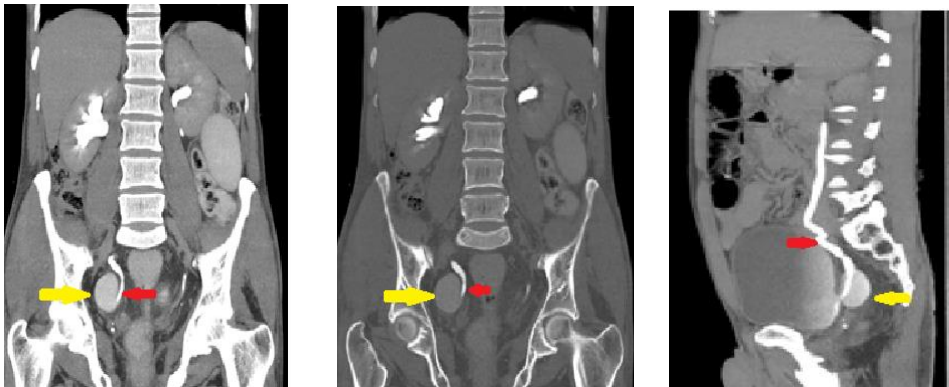


Figure 4. CT urography delayed maximum intensity projection coronal (a), (b) and sagittal (c) reformatted images revealing mild right hydroureteronephrosis. A well-defined saccular outpouching (yellow arrow) arising from the right posterolateral wall of urinary bladder is seen in the region of right vesico-ureteric junction. Mildly dilated contrast filled right ureter (red arrow) is traversing medial to the diverticulum.

### **IMAGING FINDINGS:**

With above complaints patient was referred for ultrasound abdomen and pelvis. Sonography revealed right mild hydroureteronephrosis with thin walled rounded anechoic outpouching arising from the right posterolateral wall of urinary bladder measuring 2.6 x 1.8cms with a neck measuring 4mms. The diverticulum is located immediately lateral to the right vesicoureteric junction. Rest of the urinary bladder was normal. No evidence of calculi or prostatic enlargement.

Patient was further subjected for CT urography. CT urography was performed after administering 90 cc of 300 mg/dl of non-ionic contrast on 128 slice Philips CT machine. 10 minutes delayed images were obtained. CT urography confirmed the sonographic findings. The diverticulum at the right VUJ was causing mass effect over the distal right ureter with its medial displacement. Mild upstream right hydroureteronephrosis was seen. No evidence of intra diverticular calculus or mass lesion was found.

### **DISCUSSION:**

#### **Introduction:**

Hutch diverticulum is a developmental anomaly characterized by muscle failure at or near the ureteral orifice with herniation of bladder mucosa. Diagnosis is considered in the absence of neurogenic bladder and posterior urethral valves. Hutch diverticula are exclusively seen in male sex with incidence of approximately 2 %<sup>1</sup>.

#### **Location:**

Hutch diverticula are located superolateral to the vesicoureteric junction with no involvement of trigone of urinary bladder. They are mostly unilateral with rare cases of bilaterally being reported in few case reports<sup>2</sup>.

**Epidemiology and clinical features:** Hutch diverticula are rare seen predominantly in pediatric age group before the age of 10 years. In adults they are still rarer.

Most of these diverticula are asymptomatic. Some of them may present with recurrent urinary tract infections, frequency of urination, urinary retention and obstructive features. Rarely may develop complications like secondary calculi.

**Associations:** Hutch diverticula are associated with some of the following syndromes<sup>3</sup>.

- a. Ehlers–Danlos (type 9) syndrome
- b. Menkeskinky hair syndrome
- c. Cutis Laxa syndrome (Sotos)
- d. Williams–Beuren syndrome

**Imaging:**

On ultrasound they are seen as well-defined rounded or oval anechoic outpouchings in the superolateral aspect of vesicoureteric junctions. On voiding cystourethrograms the diverticula are seen as contrast filled outpouching and if bilateral gives classic appearance of Mickey Mouse sign. There is increased incidence of associated vesico-ureteric reflux in these patients as there is hindrance in normal oblique orientation of intra vesical portion of distal ureter. CT urography provides similar findings with better anatomical delineation.

**Differential diagnosis:**

1. Bladder ears: They are anterolateral outpouchings of bladder walls into the inguinal canals.
2. Acquired bladder diverticula: They are associated with features of bladder outlet obstruction and neurogenic bladder like trabeculations and pseudodiverticulations. Acquired diverticula are multiple and have increased risk of malignancy compared to developmental<sup>4</sup>. They often require treatment. No syndromic association.

**Treatment and prognosis:**

Asymptomatic Hutch diverticula are left untreated. Complicated ones may require surgery.

## References:

1. Blane CE, Zerlin JM, Bloom DA. Bladder diverticula in children. *Radiology*. 1994;190(3):695–697. 10.1148/radiology.190.3.8115613.
2. Chawla S, Bhatt S, Tandon A, Meena G, Dangwal S. Bilateral Hutch diverticula in an elderly male: Revelation of an unknown past. *SA J Radiol*. 2020 Dec 11;24(1):1963. doi: 10.4102/sajr.v24i1.1963. PMID: 33391839; PMCID: PMC7756895.
3. Telli O, Guclu AG, Hacıyev P, Burgu B, Gogus C. A rare entity in adults: Bilateral hutch diverticulum with calculi. *Can Urol Assoc J*. 2015;9(5,6):E343–E344. 10.5489/cuaj.2327.
4. Evangelidis E, Castle P, Ostlie DJ, Snyder CL, Gatti JM, Murphy JP. Surgical management of primary bladder diverticula in children. *J Pediatr Surg*. 2005;40(4):701–703. 10.1016/j.jpedsurg.2005.01.003.